



The Hypertensive Headache: a Review

Karissa N. Arca¹ · Rashmi B. Halker Singh¹

Published online: 14 March 2019

© Springer Science+Business Media, LLC, part of Springer Nature 2019

Abstract

Purpose of Review The purpose of this review is to provide an overview and update on the common causes of headache attributed to arterial hypertension with a focus on secondary headache disorders. We will also highlight uncommon and recent findings in this area of research.

Recent Findings There is some controversy in the relationship between chronic hypertension and headache, particularly migraine; recent research suggests that there may be a link, but it is likely complex and multifactorial. Many recent studies and case reports demonstrate that the pathophysiology underlying the onset of headache as it relates to abrupt rises in blood pressure seems to lie at the cellular level and mechanically becomes an issue with disruption of the blood-brain barrier. Although not a formally defined headache entity, carotid revascularization syndrome demonstrates this phenomenon and also has a recent set of proposed criteria that include headache and elevated blood pressure.

Summary This paper reviews the various etiologies of hypertensive headaches, mostly in regard to headache as a secondary symptom of elevated blood pressure. We will also discuss trends of hypertensive headache in pregnancy. Finally, we will touch on controversy that exists in relation to chronic hypertension and its causal relationship to headache as well as the relationship between hypertension and migraine.

Keywords Secondary headache · Headache · Hypertension · Blood pressure · Arterial · Autoregulation

Introduction

Headache attributed to arterial hypertension is a secondary headache disorder of hemostasis according to the ICHD-3 [1, 2•]. The etiology of elevated blood pressure may be further specified and could occur due to pheochromocytoma, pre-eclampsia or eclampsia, autonomic disorders, or in conjunction with hypertensive encephalopathy [1]. The mechanism causing head pain during an acute hypertensive crisis is often the same despite the wide variety of illnesses. While the acutely hypertensive

patient's headache is mechanistically well defined, there is some controversy as to whether chronic hypertension predisposes towards headache or vice versa. This paper will primarily be focusing on the acute rise in blood pressure contributing to new or worsening headache and the pathophysiology behind this occurrence.

Clinical Features and Specific Causes of Arterial Hypertension Associated with Headache

Headache attributed to arterial hypertension is generally bilateral and pulsatile. It is acute in onset and related to an abrupt rise in systolic blood pressure ≥ 180 mmHg or diastolic blood pressure ≥ 120 mmHg. The headache resolves once blood pressure is normalized [1, 2•, 3]. After establishing these factors in a patient's history, in addition to the remainder of the patient's clinical history and physical exam, the clinician can work down the differential to establish the most likely cause of the acutely elevated blood pressure and subsequent headache (Fig. 1).

This article is part of the Topical Collection on *Uncommon and/or Unusual Headaches and Syndromes*

✉ Karissa N. Arca
Arca.Karissa@mayo.edu

Rashmi B. Halker Singh
Halker.Rashmi@mayo.edu

¹ Mayo Clinic Arizona, 13400 E Shea Blvd, Scottsdale, AZ 85259, USA

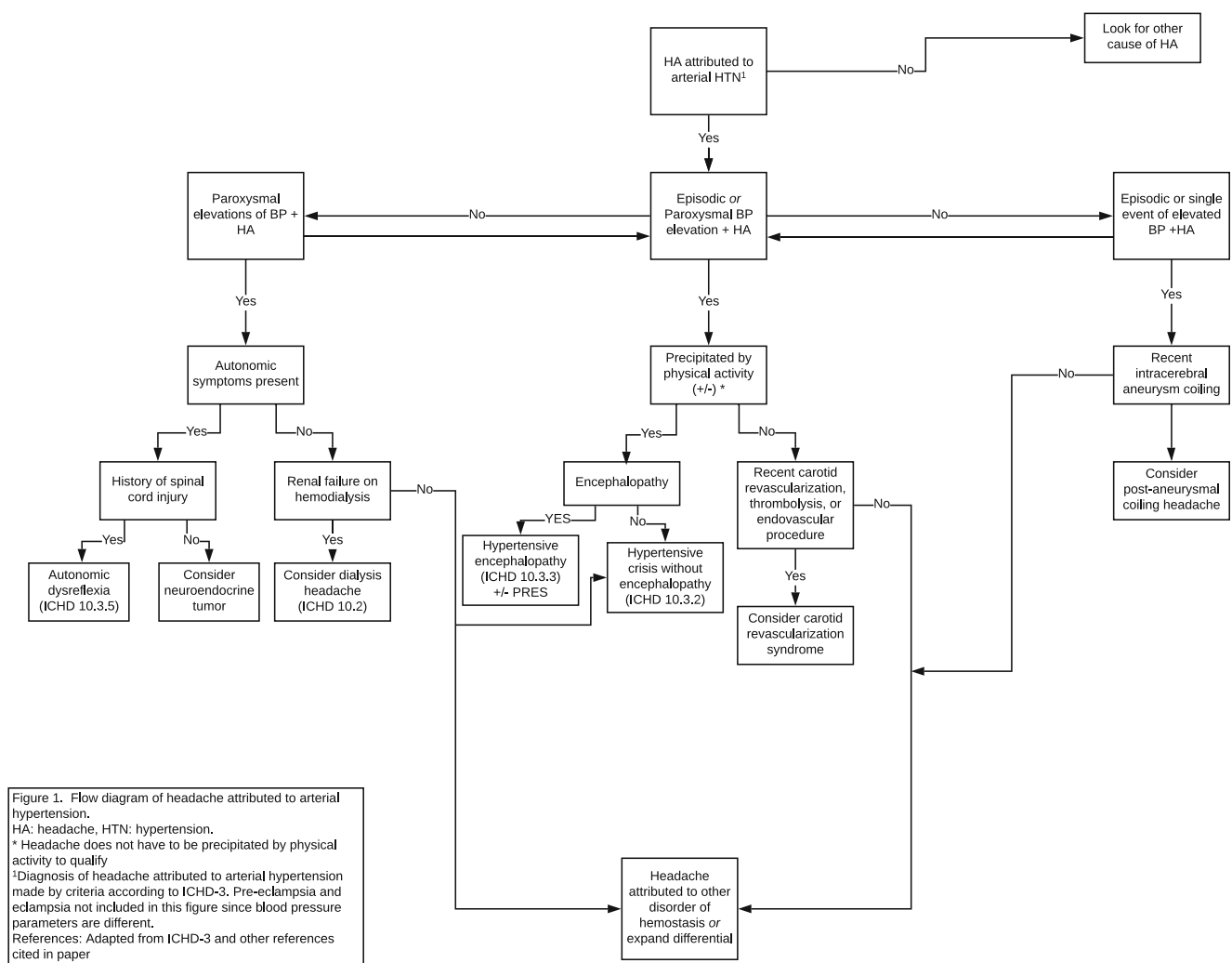


Fig. 1 Flow diagram of headache attributed to arterial hypertension

Pheochromocytoma Headaches occurring due to arterial hypertension from a known pheochromocytoma occur in discrete episodes lasting less than 1 h in duration. They are pulsatile and tend to be frontal or occipital [1]. Excess epinephrine, norepinephrine, and dopamine contribute to symptoms of hypertension, headache, palpitations, and diaphoresis, to name a few. In a recent meta-analysis, it was found that hypertensive patients with the classic triad of headache, palpitations, and diaphoresis carried a high likelihood of having pheochromocytoma with a positive LR of 14.63 [4]. Diagnosis of pheochromocytoma can be made by a 24-h urine collection of catecholamines and abdominal imaging. It should be noted that pheochromocytoma can occur in conjunction with several genetic syndromes including multiple endocrine neoplasia type 2 (MEN 2), neurofibromatosis (NF), and von Hippel-Lindau (VHL), some of which can have intracranial pathology giving rise to headache, making it particularly important to come to a clear diagnosis

[5]. Headache will resolve after resection of the pheochromocytoma [1].

A recent case report, although there are others that precede this, describes a thunderclap-like onset headache associated with a sudden spike in blood pressure that was triggered by micturition in a patient with a previously undiagnosed bladder pheochromocytoma [6•]. A key take-home point from this case is that up to 50% of patients with bladder pheochromocytomas, albeit an exceptionally rare disease, can present with thunderclap headache after micturition [6•, 7]. This certainly expands the differential of a thunderclap headache beyond that of primary central nervous system etiologies [6•].

Other Metabolic Headaches Pheochromocytoma is one category of neuroendocrine tumor that is located in the adrenal gland. The broader category of neuroendocrine tumors is defined as paraganglioma; these tumors occur in either the adrenal or extra-adrenal chromaffin tissue [8–10]. These neuroendocrine tumors can occur around autonomic nerves and major blood vessels including the aorta [8]. Paragangliomas can

present with papilledema in addition to the symptoms described above and should be kept in the differential diagnosis of patients who present with paroxysms of blood pressure elevations with headache and autonomic symptoms [8, 11].

Fluid and electrolyte shifts during hemodialysis are known to cause blood pressure changes, including hypertension. Patients often have headaches associated with hemodialysis although hypertension alone as the etiology is difficult to conclude since there are so many other metabolic derangements that could be contributing and quite often hypotension is the etiology [3]. Dialysis headache is a separate ICHD-3 diagnosis, not under the category of disorders of hemostasis [1].

Dysautonomia Autonomic dysreflexia occurs days to years after a spinal cord injury. A characteristic symptom is diaphoresis above the level of the spinal cord injury during an episode of blood pressure elevation and headache. The autonomic instability and subsequent headache can be triggered internally by bowel or bladder distension, externally by trauma, or by systemic infection, disease, or medication [1, 12•]. Up to 95% of these type of events in patients with spinal cord injuries are generated by problems with the bowel or bladder [12•]. The headache is generally thunderclap in onset with a “throbbing or pounding” quality and often has accompanying vision symptoms as well as other systemic symptoms such as nausea, chest tightness, paresthesias, and even seizures. Posterior reversible encephalopathy syndrome (PRES) has been demonstrated on imaging [12•]. A paroxysmal rise above the baseline blood pressure of ≥ 30 mmHg systolic or ≥ 20 mmHg diastolic, in addition to the characteristic findings noted above, is needed to make the diagnosis of headache attributed to autonomic dysreflexia [1]. It cannot be overemphasized that the hypertensive episodes in autonomic dysreflexia are medical emergencies. A recent case report demonstrated large intracranial hemorrhage after the development of sustained hypertension and headache in a patient that was not receiving routine intermittent catheterizations [13]. It is postulated that the headache in autonomic dysreflexia is attributable to “passive dilation of cerebral vessels” which may be related to elevated levels of prostaglandin E2 [12•, 14, 15]. Increased circulating prostaglandin has also been studied in migraine and has been shown to cause vasodilation of intracranial and extracranial vasculature [16]. Prostaglandin E2 has been studied in patients with spinal cord injury for the treatment of erectile dysfunction and was shown to lower systemic blood pressure as well [17]. Without further studies, it is difficult to know the degree to which prostaglandins are involved in the propagation of headache in these patients. There have been no recent developments in the treatment of headache in

autonomic dysreflexia as it relates to elevated prostaglandin levels.

Carotid Endarterectomy, Stenting, and Cerebral Hyperperfusion Syndrome

The entity known as cerebral hyperperfusion syndrome can occur after revascularization of the carotid artery—either endarterectomy or stenting—but more recent data suggests that it can also be a complication of thrombolytic therapy and endovascular procedures for stroke. There are no set criteria for the diagnosis, and in fact cerebral hyperperfusion syndrome (CHS) is not an entity in the ICHD-3, whereas post-endarterectomy headache is. A recent systematic review addresses key features of this syndrome that are not part of the ICHD-3 criteria for post-endarterectomy headache. These include the following: systolic blood pressure ≥ 180 mmHg, headache and accompanying focal neurologic deficits, and evidence of hyperperfusion on imaging without evidence of new ischemia (see Table 1 for more details) [1, 18••]. The headache in CHS can vary in its onset and frequency but is often severe and will herald the rise in blood pressure. Symptoms are speculated to be secondary to disordered cerebral autoregulation. Upon revascularization, blood vessels that were already maximally dilated and had reduced vasoreactivity become overpowered by the post-procedural improved blood flow which causes breakdown of the blood-brain barrier and can result in localized edema, hemorrhage, or ischemia [18••, 19].

In a recent retrospective review of post-aneurysmal embolization headaches by Choi et al., those without prior history of hypertension were found to have a higher incidence of post-embolization headache. It was hypothesized that since the vessels of normotensive patients are inherently more pliable than their hypertensive counterparts, the increase in pressure that occurs upon stenting an aneurysm in a non-chronically hypertensive individual is more than what occurs in a hypertensive individual, thereby causing headache. Blood pressures following the procedure were not documented as part of the study to know if systemic blood pressures could be attributable [20, 21]. This is an alternate theory to what is proposed in the chronically hypertensive patients that undergo carotid revascularization procedures and have hardened, poorly compliant vessels; however, it is in reference to a small, enclosed arterial territory which is the aneurysmal sac rather than the entire vessel. Both these mechanisms depict increased pressure in an enclosed space.

Baroreflex Failure Syndrome Carotid body tumors, such as paragangliomas, can compress the baroreceptors on the carotid artery and upon removal, especially when bilateral, lead to a condition known as baroreflex failure syndrome. The condition is marked by dysautonomia, headache, anxiety, and palpitations [22].

Table 1 Comparison of proposed criteria for carotid hyperperfusion syndrome post-CEA and post-endarterectomy headache as defined by the ICHD-3

	Carotid hyperperfusion syndrome (post-CEA)	Post-endarterectomy headache
Timing post-CEA	≤ 30 days	HA begins within 1 week, resolves by 1 month
Blood pressure	SBP > 180 mmHg ¹	N/A
Clinical features	New headache, seizure, hemiparesis, GCS < 15	Unilateral HA on side of CEA Occurs in cluster-like attacks lasting 2–3 h Pulsating, severe
Imaging	Evidence of hyperperfusion Can have hemorrhage or edema No ischemia or new carotid occlusion	N/A
Rule out other cause	Yes	Yes (not better accounted by other ICHD diagnosis)

¹ Does not need to have SBP > 180 mmHg if there is evidence of hyperperfusion (they function as either/or)

CEA carotid endarterectomy, GCS Glasgow Coma Scale

References for table: ICHD-3, Kirchoff-Torres et al.

Hypertensive Crisis With and Without Encephalopathy

Posterior reversible encephalopathy syndrome (PRES) classically presents with elevated blood pressure, head pain, seizure activity, change in the level of alertness, and characteristic MRI findings in the posterior circulation. Recently, a pediatric case report of PRES with headache as the only neurologic manifestation was recognized and demonstrated T2 hyperintensities in the posterior regions of the brain on MRI. The child was promptly treated with blood pressure–lowering agents, and within days, his headache and MRI findings resolved [23]. This, along with other case reports, has demonstrated that treatment of blood pressure may result in resolution of symptoms and radiographic findings [23, 24].

The etiology of PRES can vary widely, from medications including immunomodulating agents, or systemic disease such as sepsis, or autoimmune disorders all of which cause endothelial dysfunction. Alternatively, it can be caused by any insult that causes arterial hypertension enough to disturb normal cerebral autoregulation [25]. The rise in blood pressure disrupts the blood-brain barrier and normal regulation of cerebral blood pressures, permitting leakage of intravascular fluid into the brain parenchyma, similar to what occurs in carotid revascularization syndrome [23, 25]. Predisposition for PRES to affect the posterior circulation occurs due to paucity of sympathetic innervation to these vessels, thereby making them more likely to vasodilate rather than constrict and perform normal cerebral autoregulation under circumstances of increased arterial pressures compared to the anterior circulation [18•, 25].

Elevated blood pressures associated with headache but without accompanying encephalopathy have a separate ICHD-3 diagnostic category. In this category, other known entities of causality for elevated hypertension defined in the ICHD-3 must have been excluded and the patient must not be encephalopathic. Conditions that can be included in this category, or in “headache attributed to other disorder of hemostasis,” include headache due to blood pressure fluctuations of

dysautonomia including baroreflex failure syndrome as described above. Headache is a common symptom of dysautonomia; however, severe blood pressure fluctuations have been reported in the context of other autoimmune conditions such as Guillain-Barre syndrome (GBS). As of 2017, there were 15 adult cases of PRES following a recent diagnosis of GBS, the etiology of which was hypothesized to be disordered cerebral autoregulation [26].

Special Population: Pregnant Women In pregnancy, hypertension is defined as SBP ≥ 140 mmHg and DBP ≥ 90 mmHg [27, 28•] Elevated blood pressure in pregnant women is associated with a 17-fold increased risk of secondary headache [29•]. Hypertensive disorders of pregnancy associated with headache, other than arterial hypertension alone, include pre-eclampsia and eclampsia, PRES, HELLP (hemolysis, elevated liver enzymes, and low platelet count), and reversible cerebral vasoconstriction syndrome (RCVS). [28•, 29•] Women with migraine prior to pregnancy are at higher risk of these hypertensive disorders [2•, 30, 31]. Similar to non-pregnant counterparts, parous patients with headache and hypertension with concerning signs and symptoms associated with their headache (i.e., change in mental status, fever, thunderclap onset, etc.) should be promptly evaluated. Given that they are a higher risk population, hypertensive pregnant women should be closely monitored for the development of additional worrisome symptoms [32].

The diagnosis of pre-eclampsia is based on two blood pressure readings > 140/90 in a pregnant woman 4 h apart. Alternatively, a rise in the systolic pressure of ≥ 30 mmHg or diastolic pressure of ≥ 15 mmHg in 24 h accompanied by urinary protein excretion of > 0.3 g can make the diagnosis. Eclampsia occurs when the patient has a seizure. A woman with either of these conditions that is either pregnant or up to 4 weeks post-partum and whose headache improves when eclampsia or pre-eclampsia resolves can be diagnosed with headache secondary to pre-eclampsia or eclampsia. There

are no unique characteristics to the headache, but in part of the diagnostic criteria, it must have two of these characteristics: bilateral in location, pulsating, and worsened by physical activity [1]. The symptom of headache in a woman with pre-eclampsia classifies the disorder as severe pre-eclampsia [30].

A recent case report in *Clinical Nephrology* describes “mirror syndrome”—essentially a mimic of pre-eclampsia complete with hypertension and proteinuria in which the patient also complained of headache. However, the pathology lies at the growing fetus and in this case showed an abnormal placenta and fetal aneuploidy [33].

Albeit rare, vertebral artery dissection is a potential complication of the hypertensive disorders of pregnancy, particularly when there is a “hypertensive surge.” Several cases have been reported recently; none of the women presented with focal neurologic deficits and in this context, there are no guidelines as to when to investigate for a cervical arterial dissection as the cause of neck pain/headache. This is, however, an important consideration in pregnant or post-partum women who present with headache and hypertension and are refractory to simple analgesics [34].

Migraine and Hypertension

Although the vascular theory of migraine has long been overshadowed by the neurogenic theory of migraine which advocates that migraine is in fact neural in nature rather than a primary vascular process, there are still complex mechanisms at play.

Among all US emergency department visits with primary complaint of headache in 2010, 7% had SBP \geq 180 mmHg or DBP \geq 110 mmHg compared to almost 5% of those without headache as the primary complaint. A study conducted out of Montefiore used a national database in pursuit of a connection between pain levels and blood pressure elevation. Those who presented with migraine and elevated blood pressures at baseline had less headache relief in the emergency department and treatment of hypertension during a migraine attack did not correlate with headache improvement [35•]. Given the complex pathophysiology of migraine and the comorbid extraneural phenomena, it seems reasonable that lowering blood pressure may not be enough to improve head pain in a migraine patient. There is evidence suggesting that chronic hypertension is a comorbidity of migraine. In a longitudinal study published in *Neurology* in 2010, subjects with migraine with or without aura were both significantly associated with hypertension compared to subjects without headache [2•, 36]. Similarly, in a cross-sectional population-based study from an urban and rural district in Egypt investigating the prevalence of migraine across various ages and gender, hypertension was noted to be a frequent comorbidity in 12.3% of those suffering from migraine. The study did not further investigate if hypertension was more

common in chronic or episodic migraine or its relation to gender; it also did not comment on the frequency of hypertension noted in those without migraine [37].

Stiffening and poor compliance of blood vessels may be seen in migraineurs which would have the potential to contribute to hypertension and also to migraine as a vascular risk factor although further research must be done to confirm or refute this [38]. Much research has gone into the prospective connection between endothelial dysfunction and migraine, with variable results. For instance, the HUNT3 study in Norway, a large cross-sectional examination of flow-mediated dilation of the brachial artery as a sign of endothelial dysfunction in migraine, failed to show a difference between migraineurs and non-migraineurs. Other recent smaller studies, however, have shown evidence of endothelial dysfunction through demonstration of carotid intimal thickening and reduced peripheral vascular reactivity (among others) in chronic migraine compared to controls [39•]. On the other hand, some investigators have linked endothelial dysfunction only to the posterior circulation and exclusively intracranial rather than systemic [40]. In a recent systematic review in migraine with aura patients that utilized serum markers, flow-mediated dilation, carotid intimal thickness, augmentation index, and more, it was concluded that endothelial dysfunction was not a contributing vascular risk factor to stroke risk in migraine with aura [41•]. As evidenced by these many conflicting results, there is not one conclusion to be drawn regarding either the systemic or intracranial vasculature in patients with migraine. This is an area that still needs to be explored in order to provide optimization of potential risk factors and patient counseling in the management of migraine, hypertension, and aging of the younger population that is apt to develop hypertension.

A Controversial Topic: Chronic Hypertension and Headache

As noted previously, migraine may be associated with the development of chronic hypertension due to complex vascular dysfunction at the cellular level. Chronic hypertension, however, may also be associated with headache in general although the pathophysiologic mechanisms have not been elucidated. A large prospective cohort in France following patients over the last 30 years demonstrated that all types of headache (daily headache, migraine, and “other”) were positively associated with elevated diastolic blood pressures in this particular population. The elevated diastolic blood pressures measured in this study were presumably chronically elevated but were taken in one setting, averaged over six measurements and not followed throughout the study [42]. As discussed above, migraine may result in poorly compliant blood vessels which would be associated with elevations in diastolic blood

pressure. The other headache disorders in this study, however, are non-specific.

In a randomized controlled trial by Chen et al. published in 2016, the authors found that a low-sodium diet may be associated with a lower risk of headache in individuals aged 60–80 with known hypertension. Notably, these patients had hypertension at baseline and were also being treated with an anti-hypertensive medication if needed during the trial. The baseline headache frequency in these patients or prior history of migraine is unknown. Responsiveness to treatment was measured by urinary sodium excretion. Despite less headaches overall in the treatment group, there did seem to be a trend towards slowly increasing number of headaches reported over time in the control and treatment groups. Additionally, the headache frequency is not actually reported nor is the type of headache [43••]. Although this study leaves some questions unanswered, it provides valuable information for clinicians as it relates to patient care. Often, patients are interested in tackling multiple medical comorbidities with a single treatment and are also inclined to seek non-medication options to do so. Additional research in this area can help clarify the role salt reduction can play in the management of comorbid hypertension and headache.

Overall, the relationship between headache and chronic hypertension at baseline remains a controversial topic due to the paucity of data on the topic. Additionally, as discussed with migraine pathophysiology and the likely propensity for migraine to lead to hypertension, the mechanisms are complex and new information is often coming to light. We anticipate that the relationship between these two chronic conditions will become clearer as we learn more about the complexities linking the nervous and vascular systems.

Pathophysiology

In many of the above hypertensive conditions, disordered cerebral autoregulation has been the driving force for the surge of head pain that patients experience when blood pressure becomes uncontrolled. Cerebral autoregulation and the sequelae of its dysfunction are discussed above. Pain occurs because proximal portions of large intracerebral blood vessels are innervated by neurons projecting from the trigeminal ganglion. When stimulated, they project signals to the trigeminal nucleus caudalis (TNC) in the medulla which has been studied extensively in migraine and other primary headache disorders. The TNC communicates with the hypothalamus and cortical structures in a complex pain pathway [44, 45]. While this explains acute headache due to sudden rises in blood pressure, headache due to chronically sustained elevations in blood pressure is not well understood.

Recent research suggests that the autonomic nervous system may play an important role in the pathogenesis of

migraine; however, the findings are quite mixed. Sympathetic hypo-activation and hyper-activation as well as parasympathetic dysfunction at baseline in migraineurs have all been observed, making a definitive association between the autonomic nervous system and migraine difficult to confirm [46, 47•]. This is certainly another area of further research, which if expanded, in both the ictal and inter-ictal phases of migraine, may help to determine the association between hypertension and migraine beyond that of endothelial dysfunction as discussed in the section above.

Conclusion

Headache attributed to hypertension is a complex process of disordered hemostasis causing secondary headache. Notably, however, primary headache disorders such as migraine may predispose to the development of hypertensive disorders during pregnancy. The development of headache during acute elevations in blood pressure is primarily attributed to disordered cerebral autoregulation and the breakdown of the blood-brain barrier, while the association between chronic hypertension and headache is more loosely associational at this time and needs additional research. An improved understanding of the relationship between chronic hypertension and headache will hopefully provide us with better tools for treatment and counseling regarding risk factor modification.

Compliance with Ethical Standards

Conflict of Interest Karissa N. Arca and Rashmi B. Halker Singh declare no conflict of interest.

Human and Animal Rights and Informed Consent This article does not contain any studies with human or animal subjects performed by any of the authors.

References

Papers of particular interest, published recently, have been highlighted as:

- Of importance
- Of major importance

1. Headache Classification Committee of the International Headache Society (IHS) The international classification of headache disorders, 3rd edition Cephalgia : an international journal of headache 2018;38(1):1–211. doi:<https://doi.org/10.1177/0333102417738202>.
2. Finocchi C, Sassos D. Headache and arterial hypertension. *Neurol Sci* : official journal of the Italian Neurological Society and of the Italian Society of Clinical Neurophysiology. 2017;38(Suppl 1):67–72. <https://doi.org/10.1007/s10072-017-2893-x> **Only other narrative review on this subject in recent literature.**

3. Lagman-Bartolome AM, Gladstone J. Metabolic headaches. *Neurol Clin*. 2014;32(2):451–69. <https://doi.org/10.1016/j.ncl.2013.11.011>.
4. Pourian M, Mostafazadeh DB, Soltani A. Does this patient have pheochromocytoma? A systematic review of clinical signs and symptoms. *J Diab Metab Disord*. 2016;15(1):11. <https://doi.org/10.1186/s40200-016-0230-1>.
5. Tsirlin A, Oo Y, Sharma R, Kansara A, Gliwa A, Banerji MA. Pheochromocytoma: a review. *Maturitas*. 2014;77(3):229–38. <https://doi.org/10.1016/j.maturitas.2013.12.009>.
6. Han YJ, Ock SY, Kim EJ, Shin HS, Jung YS, Rim H. Thunderclap-like headache triggered by micturition and angina as an initial manifestation of bladder pheochromocytoma. A case report. *Sao Paulo Med J = Revista paulista de medicina*. 2015;133(2):154–9. <https://doi.org/10.1590/1516-3180.2013.6890002> **Important to keep these rare entities of hypertension-related thunderclap headache in mind.**
7. Beilan JA, Lawton A, Hajdenberg J, Rosser CJ. Pheochromocytoma of the urinary bladder: a systematic review of the contemporary literature. *BMC Urol*. 2013;13:22. <https://doi.org/10.1186/1471-2490-13-22>.
8. Balasubramanian G, Nellaippan V. Functional paraganglioma. *BMJ case reports*. 2014;2014:bcr2013203425. <https://doi.org/10.1136/bcr-2013-203425>.
9. Wuyts L, Pouillon M, Huyghe M, Ruysers N, Goovaerts G, Spaepen M. Palpitations, headache and night sweats caused by a retroperitoneal mass: case report and short review. *BJR case reports*. 2017;3(4):20170035. <https://doi.org/10.1259/bjrcr.20170035>.
10. Pichler R, Heidegger I, Klinglmaier G, Kroiss A, Uprimny C, Gasser RW, et al. Unrecognized paraganglioma of the urinary bladder as a cause for basilar-type migraine. *Urol Int*. 2014;92(4):482–7. <https://doi.org/10.1159/000348829>.
11. Berradi S, Hafidi Z, Daoudi R. Phaeochromocytoma revealed by a stellate neuroretinitis. *Lancet Diab Endocrinol*. 2014;2(8):676. [https://doi.org/10.1016/s2213-8587\(14\)70129-9](https://doi.org/10.1016/s2213-8587(14)70129-9).
12. Furlan JC. Headache attributed to autonomic dysreflexia: an underrecognized clinical entity. *Neurology*. 2011;77(8):792–8. <https://doi.org/10.1212/WNL.0b013e31822aff11> **Although not recent, this is one of the most comprehensive narrative reviews of autonomic dysreflexia.**
13. Vaidyanathan S, Soni BM, Hughes PL, Oo T. Fatal cerebral hemorrhage in a tetraplegic patient due to autonomic dysreflexia triggered by delay in emptying urinary bladder after unsuccessful intermittent catheterization by carer: lessons learned. *Int Med Case Rep J*. 2018;11:53–8. <https://doi.org/10.2147/imcrj.s143077>.
14. Naftchi NE, Tuckman J. Hypertensive crises in spinal man. *Am Heart J*. 1979;97(4):536–8.
15. Schumacher GA, Guthrie TC. Studies on headache: mechanism of headache and observations on other effects induced by distention of bladder and rectum in subjects with spinal cord injuries. *AMA Arch Neurol Psychiatr*. 1951;65(5):568–80.
16. Antonova M. Prostaglandins and prostaglandin receptor antagonism in migraine. *Dan Med J*. 2013;60(5):B4635.
17. Krassioukov A, Warburton DE, Teasell R, Eng JJ. A systematic review of the management of autonomic dysreflexia after spinal cord injury. *Arch Phys Med Rehabil*. 2009;90(4):682–95. <https://doi.org/10.1016/j.apmr.2008.10.017>.
18. Kirchoff-Torres KF, Bakradze E. Cerebral Hyperperfusion Syndrome After Carotid Revascularization and Acute Ischemic Stroke. *Curr Pain Headache Rep*. 2018;22(4):24. <https://doi.org/10.1007/s11916-018-0678-4> **Recent narrative review that outlines cerebral hyperperfusion syndrome and newly proposed criteria for its diagnoses and compares this to other ICHD-3 diagnoses.**
19. Farooq MU, Goshgarian C, Min J, Gorelick PB. Pathophysiology and management of reperfusion injury and hyperperfusion syndrome after carotid endarterectomy and carotid artery stenting. *Exp Transl Stroke Med*. 2016;8(1):7. <https://doi.org/10.1186/s13231-016-0021-2>.
20. Choi KS, Lee JH, Yi HJ, Chun HJ, Lee YJ, Kim DW. Incidence and risk factors of postoperative headache after endovascular coil embolization of unruptured intracranial aneurysms. *Acta Neurochir*. 2014;156(7):1281–7. <https://doi.org/10.1007/s00701-014-2095-8>.
21. Hwang G, Jeong EA, Sohn JH, Park H, Bang JS, Jin SC, et al. The characteristics and risk factors of headache development after the coil embolization of an unruptured aneurysm. *AJNR Am J Neuroradiol*. 2012;33(9):1676–8. <https://doi.org/10.3174/ajnr.A3018>.
22. Ghali MGZ, Srinivasan VM, Hanna E, DeMonte F. Overt and subclinical baroreflex dysfunction after bilateral carotid body tumor resection: pathophysiology, diagnosis, and implications for management. *World Neurosurg*. 2017;101:559–67. <https://doi.org/10.1016/j.wneu.2017.02.073>.
23. Milani GP, Edefonti A, Tardini G, Arturi E, Cinnante CM, Laicini EA, et al. Severe and isolated headache associated with hypertension as unique clinical presentation of posterior reversible encephalopathy syndrome. *BMC Pediatr*. 2014;14:190. <https://doi.org/10.1186/1471-2431-14-190>.
24. Christopoulou F, Rizos EC, Kosta P, Argyropoulou MI, Elisaf M. Does this patient have hypertensive encephalopathy. *J Am Soc Hypertens : JASH*. 2016;10(5):399–403. <https://doi.org/10.1016/j.jash.2016.01.020>.
25. Fischer M, Schmutzhard E. Posterior reversible encephalopathy syndrome. *J Neurol*. 2017;264(8):1608–16. <https://doi.org/10.1007/s00415-016-8377-8>.
26. Alrohimi A, Jassal R. Headache in Guillain-Barre syndrome: diagnostic and management implications. *Can J Neurol Sci Le J: canadien des sciences neurologiques*. 2018;45(2):240–2. <https://doi.org/10.1017/cjn.2017.247>.
27. Raffaelli B, Siebert E, Korner J, Liman T, Reuter U, Neeb L. Characteristics and diagnoses of acute headache in pregnant women - a retrospective cross-sectional study. *J Headache Pain*. 2017;18(1):114. <https://doi.org/10.1186/s10194-017-0823-1>.
28. Robbins MS, Farmakidis C, Dayal AK, Lipton RB. Acute headache diagnosis in pregnant women: a hospital-based study. *Neurology*. 2015;85(12):1024–30. <https://doi.org/10.1212/wnl.0000000000001954> **Important single-center retrospective study that outlines the headache disorders experienced by pregnant women.**
29. Robbins MS. Headache in pregnancy. *Continuum (Minneapolis, Minn)*. 2018;24(4, Headache):1092–107. <https://doi.org/10.1212/con.0000000000000642> **Most recent comprehensive review of headache in pregnancy and includes the impact of hypertension during pregnancy and the comorbid risk factor of migraine during pregnancy.**
30. Crovetto F, Somigliana E, Peguero A, Figueras F. Stroke during pregnancy and pre-eclampsia. *Curr Opin Obstet Gynecol*. 2013;25(6):425–32. <https://doi.org/10.1097/gco.0000000000000024>.
31. Facchinetti F, Allais G, Nappi RE, D'Amico R, Marozio L, Bertozzi L, et al. Migraine is a risk factor for hypertensive disorders in pregnancy: a prospective cohort study. *Cephalalgia : an international journal of headache*. 2009;29(3):286–92. <https://doi.org/10.1111/j.1468-2982.2008.01704.x>.
32. Sperling JD, Dahlke JD, Huber WJ, Sibai BM. The role of headache in the classification and management of hypertensive disorders in pregnancy. *Obstet Gynecol*. 2015;126(2):297–302. <https://doi.org/10.1097/aog.0000000000000966>.

33. Banoth P, Chaudhary K. Proteinuria: a presenting manifestation of mirror syndrome in pregnancy. *Clin Nephrol*. 2018;90(1):60–3. <https://doi.org/10.5414/cn109299>.
34. Shanmugalingam R, Reza Pour N, Chuah SC, Vo TM, Beran R, Hennessy A, et al. Vertebral artery dissection in hypertensive disorders of pregnancy: a case series and literature review. *BMC Pregnancy and Childbirth*. 2016;16(1):164. <https://doi.org/10.1186/s12884-016-0953-5>.
35. Friedman BW, Mistry B, West JR, Wollowitz A. The association between headache and elevated blood pressure among patients presenting to an ED. *Am J Emerg Med*. 2014;32(9):976–81. <https://doi.org/10.1016/j.ajem.2014.05.017> **Retrospective review examining the association and outcomes between hypertension and headache in the emergency department and the subsequent treatment of hypertension, particularly in those with known primary headache disorders (i.e., migraine). An important situation many neurologists and ED providers are faced with to determine if symptomology requires further workup or treatment.**
36. Bigal ME, Kurth T, Santanello N, Buse D, Golden W, Robbins M, et al. Migraine and cardiovascular disease: a population-based study. *Neurology*. 2010;74(8):628–35. <https://doi.org/10.1212/WNL.0b013e3181d0cc8b>.
37. Kandil MR, Hamed SA, Fadel KA, Khalifa HE, Ghanem MK, Mohamed KO. Migraine in Assiut Governorate, Egypt: epidemiology, risk factors, comorbid conditions and predictors of change from episodic to chronic migraine. *Neurol Res*. 2016;38(3):232–41. <https://doi.org/10.1080/01616412.2015.1114232>.
38. Sacco S, Ripa P, Grassi D, Pistoia F, Ornello R, Carolei A, et al. Peripheral vascular dysfunction in migraine: a review. *J Headache Pain*. 2013;14:80. <https://doi.org/10.1186/1129-2377-14-80>.
39. Gonzalez-Quintanilla V, Toriello M, Palacio E, Gonzalez-Gay MA, Castillo J, Montes S, et al. Systemic and cerebral endothelial dysfunction in chronic migraine. A case-control study with an active comparator. *Cephalalgia: an international journal of headache*. 2016;36(6):552–60. <https://doi.org/10.1177/0333102415607857> **Important area of both established and up and coming research into the pathophysiology of migraine.**
40. Rajan R, Khurana D, Lal V. Interictal cerebral and systemic endothelial dysfunction in patients with migraine: a case-control study. *J Neurol Neurosurg Psychiatry*. 2015;86(11):1253–7. <https://doi.org/10.1136/jnnp-2014-309571>.
41. Butt JH, Franzmann U, Kruuse C. Endothelial function in migraine with aura - a systematic review. *Headache*. 2015;55(1):35–54. <https://doi.org/10.1111/head.12494> **Important area of both established and up and coming research into the pathophysiology of migraine.**
42. Courand PY, Serraille M, Girerd N, Demarquay G, Milon H, Lantelme P, et al. The paradoxical significance of headache in hypertension. *Am J Hypertens*. 2016;29(9):1109–16. <https://doi.org/10.1093/ajh/hpw041>.
43. Chen L, Zhang Z, Chen W, Whelton PK, Appel LJ. Lower sodium intake and risk of headaches: results from the trial of nonpharmacologic interventions in the elderly. *Am J Public Health*. 2016;106(7):1270–5. <https://doi.org/10.2105/ajph.2016.303143> **Study investigating other metabolic connections to headache and hypertension: an important stepping stone for further research.**
44. Cutrer FM. Pathophysiology of migraine. *Semin Neurol*. 2010;30(2):120–30. <https://doi.org/10.1055/s-0030-1249222>.
45. Arca KN, Halker Singh RB. SUNCT and SUNA: an update and review. *Curr Pain Headache Rep*. 2018;22(8):56. <https://doi.org/10.1007/s11916-018-0707-3>.
46. Matei D, Constantinescu V, Corciova C, Ignat B, Matei R, Popescu CD. Autonomic impairment in patients with migraine. *Eur Rev Med Pharmacol Sci*. 2015;19(20):3922–7.
47. Miglis MG. Migraine and autonomic dysfunction: which is the horse and which is the jockey? *Curr Pain Headache Rep*. 2018;22(3):19. <https://doi.org/10.1007/s11916-018-0671-y> **Another area of research that may help establish the pathophysiologic link between migraine and hypertension and other blood pressure changes.**

Publisher's Note Springer Nature remains neutral with regard to jurisdictional claims in published maps and institutional affiliations.