

# Surgical Therapy of Temporal Triggered Migraine Headache

Nicolò Bertozzi, MD\*†  
 Francesco Simonacci, MD\*†  
 GianLuigi Lago, MD\*†  
 Chiara Bordin, MSc\*†  
 Edoardo Raposio, MD,  
 PhD, FICS\*†

**Background:** The auriculotemporal and zygomaticotemporal nerves are the 2 primary trigger points in the temporal area of migraine headache. Different surgical approaches are described in literature, either open or endoscopic ones.

**Methods:** We described and delineated the currently adopted strategies to treat temporal trigger points in migraine headache. Furthermore, we reported our personal experience in the field.

**Results:** Regardless of the type of approach, outcomes observed were similar and ranged from 89% to 67% elimination / >50% reduction rates. All procedures are minimally invasive and only minor complications are reported, with an incidence ranging from 1% to 5%.

**Conclusions:** Just like upper limb compressive neuropathies, migraine headache is believed to be caused by chronic compression of peripheral nerves (ie, the terminal branches of trigeminal nerve) caused by surrounding structures (eg, muscles, vessels, and fascial bands) the removal of which eventually results in improvement or elimination of migraine attacks. Particular attention should be paid to the close nerve/artery relationship often described in anatomical studies and clinical reports. (*Plast Reconstr Surg Glob Open* 2018;6:e1980; doi: 10.1097/GOX.0000000000001980; Published online 17 December 2018.)

## INTRODUCTION

Following the studies of Guyuron<sup>1-10</sup> and those of other independent groups, migraine surgery has been widely accepted as an effective surgical solution for chronic headaches refractory to medical and conservative treatment. Although the pathophysiology of migraine headaches (MH) remains a matter of debate, it's a common belief that chronic compression to the terminal branches of trigeminal nerve caused by surrounding structures (eg, muscles, vessels, and fascial bands) is responsible for its origin. Four main trigger zones of MH are amenable to surgical decompression: frontal (site I: supraorbital and supratrochlear nerves), temporal (site II: zygomatic-temporal branch of the trigeminal nerve), endonasal (site III: trigeminal end branches), and occipital (site IV: great oc-

cipital nerve).<sup>11</sup> The auriculotemporal nerve (ATN) and lesser occipital nerve, site V and VI, respectively, are commonly described as less relevant trigger sites<sup>12</sup> (Table 1).

This article aims to describe and carefully delineate the currently adopted strategies to treat temporal trigger points in MH sufferers. The ATN and zygomaticotemporal nerves (ZTN) are the 2 primary trigger points in the temporal area. Different surgical approaches are described in literature, either open or endoscopic ones. Regardless of the surgical approach chosen, the procedure aims at decompressing the putative irritated nerves from the surrounding offending structures. Therefore, a clear anatomical knowledge of this area should be kept in mind.

## RELEVANT ANATOMY

Many anatomical studies have been carried out to describe the anatomy of the temple, particularly the course of the ATN and ZTN and the structure that could potentially compress them. The ZTN is one of the terminal branches of the maxillary division (V<sub>2</sub>) of the trigeminal nerve. It originates from the bifurcation of the zygomatic branch within a canal in the zygomatic bone, from which it exits in the anterior part of the temporal fossa 17 mm posterolateral and 6.5 mm cephalad from the lateral canthus.<sup>13</sup> Then, it as-

From the \*Department of Medicine and Surgery, Plastic Surgery Division, University of Parma, Parma, Italy; †Department of Surgery, Cutaneous, Mini-invasive, Regenerative and Plastic Surgery Unit, Parma University Hospital, Parma, Italy.

Received for publication April 13, 2018; accepted August 22, 2018.

Copyright © 2018 The Authors. Published by Wolters Kluwer Health, Inc. on behalf of The American Society of Plastic Surgeons. This is an open-access article distributed under the terms of the Creative Commons Attribution-Non Commercial-No Derivatives License 4.0 (CCBY-NC-ND), where it is permissible to download and share the work provided it is properly cited. The work cannot be changed in any way or used commercially without permission from the journal.

DOI: 10.1097/GOX.0000000000001980

**Disclosure:** The authors have no financial interest to declare in relation to the content of this article. The Article Processing Charge will be paid with funding of the University of Parma, Italy.

**Table 1. Migraine Headache Trigger Sites, Peripheral Nerves Involved, and Putative Anatomical Compressing Structures**

Migraine Headache Trigger Sites	Involved Trigeminal Peripheral Nerves	Potential Compressing Points
Site I – frontal	Supraorbital and supratrochlear nerve (V <sub>1</sub> )	Glabellar muscles Comitant named arteries STA Bony foramina Fascial bands
Site II – temporal	Zygomatic-temporal nerve (V <sub>2</sub> )	Temporalis muscle and fascia STA Sentinel vein
Site III – endonasal	Trigeminal end branches (V <sub>2</sub> )	Deviated septum Turbinates – septum contact Concha bullosa Septa bullosa Other intranasal abnormalities
Site IV – occipital	Greater occipital nerve (C <sub>2</sub> )	Occipitalis, trapezius, and semispinalis capitis muscles and fascia Fascial bands Occipital artery Lymph nodes
Site V – auriculotemporal	Auriculotemporal nerve (V <sub>2</sub> )	Superior temporal artery Preauricular fascial bands
Site VI – lesser occipital	Lesser occipital nerve (C <sub>2</sub> )	Trapezius and sternocleidomastoid muscles Fascial bands Occipital artery

cends between the bone and the temporalis muscle, piercing the deep temporal fascia approximately 2 cm above the zygomatic arch arborizing within the subcutaneous tissues to innervate the skin of the temporal area.<sup>13</sup> Three accessory branches can be found either superiorly, immediately adjacent or posterolateral to the main branch. Whenever a posterolateral branch is present, it usually runs horizontally, connecting the ZTN with the ATN.<sup>13</sup>

The ATN is also one of the terminal branches of the V<sub>2</sub> division of the trigeminal nerve.<sup>14-17</sup>

It provides innervation to: temporomandibular joint, parotid gland, external acoustic meatus, anterior auricle, zygoma, and superficial temporal region. It originates from mandibular division of the trigeminal nerve within the pterygopalatine fossa, it turns around the inferior border of the zygomatic arch in close proximity to the temporomandibular joint, and then it reaches the facial soft tissue running cranially within the temporoparietal fascia superficial to the superficial temporal artery (STA). The ATN has a single main trunk in 78.5% of the cases while in the remaining 21.5% it's duplicated at the retromandibular space.<sup>11</sup>

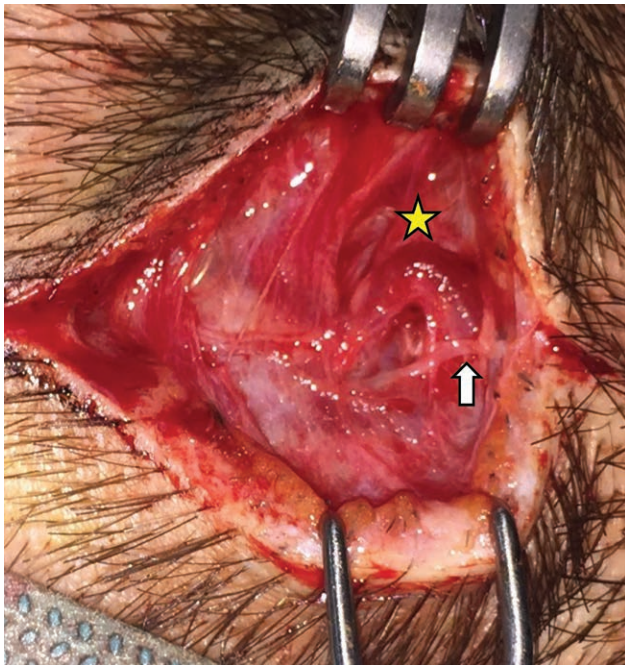
Whenever the ATN is duplicated, both trunks accede to the superficial layers at approximately 10 mm above the middle of the tragus.<sup>18</sup> The anterior trunk runs cranially parallel to the STA, while the posterior can be found into the subcutaneous layer 1 mm anterior to the auricle. Communicating branches can be present at this level.

The ATN has been traditionally described to divide into several superficial temporal branches (STb) innervating the skin of the temple. Gülekon et al.<sup>19</sup> demonstrated that the nerve has one branch in 50% of specimens, while multiple branches (up to 4) can be present in the other 50% of specimens. Baumel et al.<sup>20</sup> identified 5–9 terminal STbs. Iwanaga et al.<sup>17</sup> reported from 2 to 7 STb, which branched from the main trunk at a distance of 6.19–25.66 mm vertically and 3.45–11.88 mm horizontally from the middle of the tragus. Furthermore, from 0 to 4 communicating branches were reported, which occasionally formed a loop or “ansa.” Andersen et al.<sup>21</sup> reported that the ATN might have a single main branch, a diffuse branching pattern, or divide into smaller branches, herein described as STb (Table 2).

Three potential compression points of the ATN along its course have been described: 2 preauricular fascial bands (the most caudal one is found 13.1±5.9 mm anterior and 5.0±7.0 mm superior to the most anterosuperior point of the external auditory meatus, whereas the most cranial one is located 11.9±6.0 mm anterior and 17.2±10.4 mm superior to the same landmark) and the STA.<sup>14</sup> Indeed, a

**Table 2. Zygomatic-temporal and Auriculotemporal Nerves' Relevant Anatomy**

Temporal Trigger Site	Involved Trigeminal Nerve	Anatomy of Relevant Temporal Nerves		
		Origin – Exit Point	Main Course	Branching Pattern
Site II – temporal	Zygomatic-temporal nerve (V <sub>2</sub> )	<ul style="list-style-type: none"> <li>- Origin: bifurcation of the zygomatic branch within a canal in the zygomatic bone</li> <li>- Exit point: anterior temporal fossa 17 mm posterolateral and 6.5 mm cephalad from the lateral canthus</li> </ul>	<ul style="list-style-type: none"> <li>- Initial ascending course between bone and temporalis muscle</li> <li>- Pierces deep temporal fascia 2 cm above the zygomatic arch</li> <li>- Arborizes within subcutaneous tissues</li> </ul>	<ul style="list-style-type: none"> <li>- Three accessory branches can be found: superiorly, immediately adjacent or posterolateral to the main branch.</li> <li>- Whenever present, posterolateral branch is anastomosed with the auriculotemporal nerve</li> </ul>
Site V – auriculotemporal	Auriculotemporal nerve (V <sub>2</sub> )	<ul style="list-style-type: none"> <li>- Origin: mandibular division of trigeminal nerve within pterygo-palatin fossa</li> <li>- Exit point: turns around the inferior border of the zygomatic arch in close proximity to the temporomandibular joint</li> </ul>	<ul style="list-style-type: none"> <li>- Runs cranially within the temporoparietal fascia superficial to the STA.</li> <li>- When duplicated, communicating branches are found into the subcutaneous layer 1 mm anterior to the auricle</li> </ul>	<ul style="list-style-type: none"> <li>- 78.5% single main trunk</li> <li>- 21.5% duplicates at the retromandibular space</li> <li>- 2-9 superficial terminal branches</li> </ul>



**Fig. 1.** Dilated left STA (yellow star) intertwined with the left auriculotemporal nerve (white arrow).

close relationship between these 2 structures is reported with different percentage in literature.

Chim et al.<sup>14</sup> found as high as 80% close relationship of the ATN with the STA with 3 patterns of interaction: single STA crossing over of the ATN (62.5%), helical intertwining (18.8%), and single ATN crossing over the STA (18.8%). Conversely, Janis et al.<sup>15</sup> found a 34% contiguous relationship between ATN and STA. Furthermore, only 2 patterns of interaction were reported: single, short, discrete intersection (88.2%), and helical intertwining (11.8%; Fig. 1). Anatomic studies describe the course of nerves and their relationships with arteries in a “normal” population, with no recorded history of migraine. Hence, patients with

migraine could experience headache because their anatomic relationships are not normal (Table 3).

### TRIGGER POINT DETECTION

Detecting the precise site of pain onset (trigger point) is of paramount importance for a successful outcome (Table 4). Indeed, partial or nonresponse to surgery may be primarily related to failure in recognizing all the trigger points. Botulinum toxin injections, nerve blocks, portable Doppler devices were all investigated.<sup>12</sup> Botulinum toxin administration proved to be useless since lack or incomplete response does not automatically exclude the suspected trigger point, since close nerve-artery relationship might be the main cause of MH.<sup>12</sup> Nerve blocks could be helpful; however, patients should be seen in the office during a MH attack. Finally, handheld Doppler devices proved to be useful in detecting migraine trigger points, especially because the nerve-artery crossover or close relationship might be the implicated in the headache pathogenesis.<sup>12</sup>

Nevertheless, clinical findings are still the best way to identify trigger points’ location.

Patients suffering from site II temporal migraine usually report diffuse low temporal pain closer to the lateral canthus, whereas those with site V involvement tend to complain of more superior pain localized in the temple or alternatively moderate-to-severe pain on the preauricular area, often spreading to the ipsilateral temple.<sup>22</sup>

Patients usually report diffuse headache; however, they can precisely pinpoint with one fingertip the precise location of the tender spot from where the MH attack begins, and that is where the surgical treatment should be carried out. Furthermore, simple compression of the tender spot by the fingertip of the surgeon during physical examination can usually evoke pain confirming the diagnosis. Therefore, it is the authors’ experience that accurate history and careful physical examination can safely detect all patient’s trigger points, while positive handheld Doppler signal can corroborate the diagnosis.

**Table 3. Auriculotemporal Nerve Potential Compression Points Anatomy**

Auriculotemporal Nerve Potential Compression Points	
Superior preauricular fascial band	13.1±5.9 mm anterior and 5.0±7.0 mm superior to the most anterosuperior point of the external auditory meatus.
Inferior preauricular fascial band	11.9±6.0 mm anterior and 17.2±10.4 mm superior to the most anterosuperior point of the external auditory meatus.
STA	Chim et al. <sup>14</sup>
	- Reported 80% close relationship of the ATN with the STA with three patterns of interaction: single STA crossing over of the ATN (62.5%), helical intertwining (18.8%), and single ATN crossing over the STA (18.8%).
	- Single intersection site was found at a mean distance of 19.2±10.0 mm anterior and 39.5±16.6 mm superior to the most anterosuperior point of the external auditory meatus.
	- Helical intertwining relationship had a mean length of 10.3±0.4 mm; inferior limit was at a mean distance of 20.0±15.6 mm anterior and 53.7±4.7 mm superior to the most anterosuperior point of the external auditory meatus, superior limit was at a mean distance of 24.7±17.9 mm anterior and 62.7±3.8 mm superior to the same anatomical landmarks.
	Janis et al. <sup>15</sup>
	- Reported a 34% contiguous relationship between ATN and STA with only 2 patterns of interaction: single, short, discrete intersection (88.2%), and helical intertwining (11.8%).
	- Single intersection site was found on average 107.88±17.73 mm lateral to the midline and 37.53±15.29 mm cranial to the nasion-lateral orbit line.
	- Helical intertwining relationship had a mean length of 21 mm, starting inferiorly 123 mm lateral to the midline and 25 mm cranial to the nasion-lateral orbit line, ending superiorly 117 mm lateral to the midline and 38 mm cranial to the nasion-lateral orbit line.

**Table 4. Trigger Point Detection Techniques’ Advantages and Drawbacks**

Trigger Point Detection Technique	Advantages	Drawbacks
Clinical findings	Still the gold standard detection technique for trigger points’ location, patients can easily recognize the starting point of their MH attacks.	It’s a subjective approach and relies in patients’ ability to report their trigger point locations.
Botulinum injections	It can be applied even when patients aren’t experiencing MH attacks.	It’s costly, it requires second office evaluation, thus it can’t be easily employed for patients that live far or for off the country ones. Lack or incomplete response does not automatically exclude the suspected trigger point, since close nerve-artery relationship might be the main cause of MH.
Local anesthetics injections	It is helpful since it doesn’t require second office-based visit. It’s cheap.	Patients should be seen in the office during a MH attack.
Handheld Doppler	It’s the second most useful detecting technique of migraine trigger points, especially because positive Doppler sing 100% correlate with nerve-artery crossover or close relationship intraoperatively. It’s cheap.	It’s subjective. Absent Doppler sign does not automatically exclude the suspected trigger point.

**SURGICAL PROCEDURE**

Endoscopic or open surgical approaches are the only viable techniques to alleviate migraine headaches.

**Site II—Zygomaticotemporal Nerve Deactivation**

Guyuron<sup>1,3</sup> has developed the technique for endoscopic decompression of ZTN. The procedure is performed under local anesthesia; two 1.5-cm incisions are made on each side at approximately 7 and 10 cm from the midline in the hair-bearing area of the scalp. Incisions are deepened to the deep temporalis fascia by means of Metzenbaum scissors to expose the deep temporal fascia and then a periosteal elevator is used for medial, lateral, cephalad, and caudal dissection to accommodate the endoscope. Under endoscopic view, the ZTN is exposed, isolated, and either avulsed by removing approximately 2.5 cm of the nerve or decompressed by widening the fascia opening and cauterizing the zygomaticotemporal artery.<sup>23</sup>

Gfrerer et al.<sup>24</sup> and Peled<sup>25</sup> have described open approaches for decompression surgery of the ZTN through transpalpebral and temporal hair-bearing area incisions, respectively. Again, careful dissection is performed along the deep temporal fascia to prevent lesions to the temporal branch of the facial nerve. Once exposed, the ZTN is either avulsed or decompressed under direct vision.

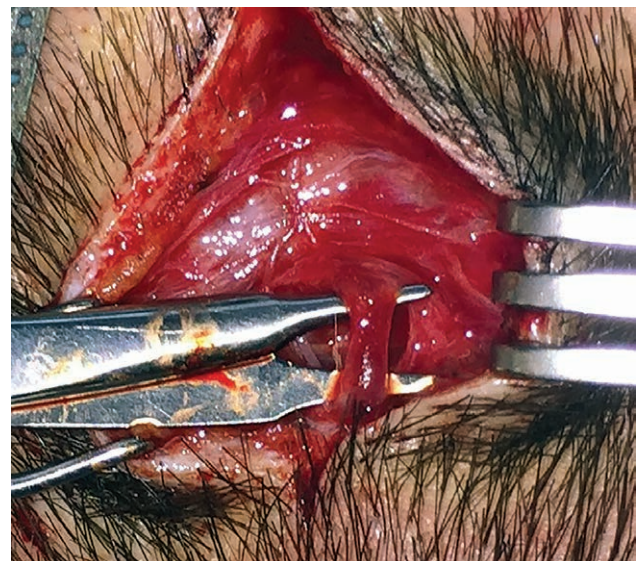
**Site V—Auriculotemporal Nerve Deactivation**

ATN deactivation surgery is usually performed with an open approach only, since the nerve lies within the superficial temporal fascia just beneath the subcutaneous tissue, where the STA can be found too. If site V surgery has to be done in conjunction with site II, 5–7 port incision is regularly designed for endoscopic decompression of ZTN and a further 1.5-cm lateral incision is made locating the tender point with the aid of handheld Doppler. Dissection is made with blunt tipped scissors to expose the ATN and the STA taking care not to injure the temporal branch of the facial nerve (even though it usually lies in a deeper plane). Then once the ATN and STA are isolated, the last one can be either cauterized or simply ligated.<sup>26</sup>

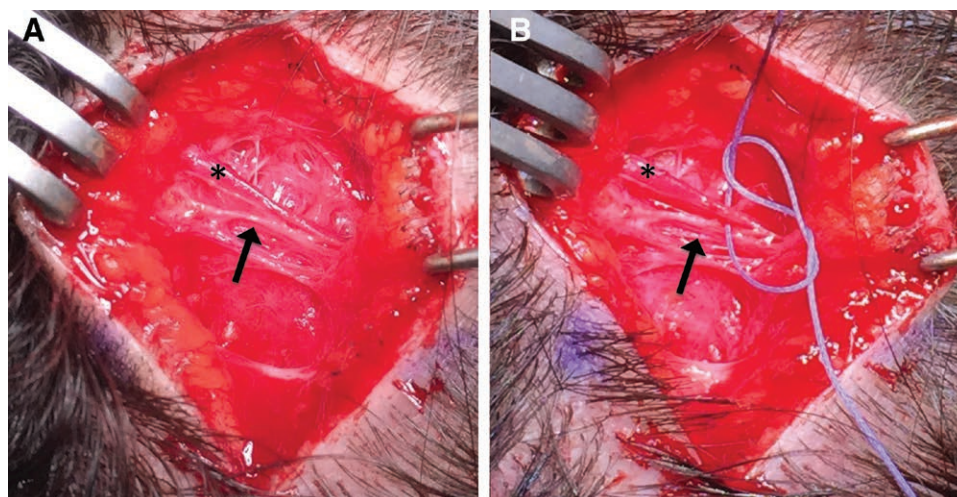
If the trigger point lies beyond the hairline or in proximity of the temporal branch of facial nerve, ATN and STA exposure, isolation, and ligation of the artery can be performed with a 1.5-cm incision 0.5 cm anterior to the tragus, just above the temporo-mandibular joint. At this level, the ATN is identified first, while the STA is located just deeper to it.

**Authors’ Experience**

We perform both procedures under local assisted anesthesia.<sup>11</sup> Addressing ZTN, we make 3-cm cutaneous incision 8–10 mm behind the temporal hairline and take dissection deep to the deep temporal fascia by the blunt tip scissors. We open the inferior temporal septum exposing the inferior temporal compartment that contains the ZTN, sentinel vessels, and temporal branches of facial nerve (that must be carefully preserved by incorporating it in the roof of the elevated flap). Then we widen the exit



**Fig. 2.** Intraoperative picture: Isolation of the left STA.



**Fig. 3.** Intraoperative picture of a right-sided temporal migraine deactivation surgery. A, The auriculotemporal nerve (black arrow) and the STA (black star) are exposed and isolated. B, Then the STA is ligated proximally and distally at the operative site.

of the ZTN through temporal muscle and fascia, and the sentinel vessels are cauterized only when patients describe a pulsating pain in the temporal region.

For ATN decompression surgery, we usually mark a 1.5-cm incision where patients pinpoint the tender spot. A handheld Doppler is regularly used to locate the STA, since we observed 100% correlation rate between the trigger point identified and a close ATN-STA relationship (being either a simple crossover or a helical intertwining). Once the incision is made, dissection is taken with the help of blunt tipped scissors to expose and isolate both ATN and STA (Fig. 2), which is ligated both proximally and caudally to the area of nerve-artery intersection (Figs. 3, 4).

## RESULTS

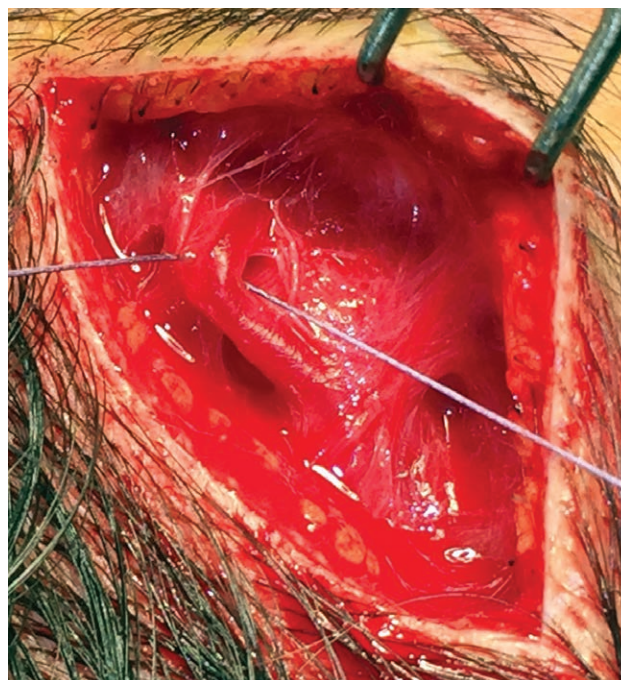
These procedures are usually performed as 1-day surgery. No drainage tubes usually need to be positioned. Patients are commonly permitted to resume ordinary daily activities starting from second postoperative day (POD), light exercise by seventh POD, and regular exercise by 21st POD.<sup>11</sup>

### Outcome

Authors have reported their results following temporal migraine deactivation surgeries.<sup>23-28</sup> Regardless of the type of approach, deactivated trigger point, and surgery performed, outcomes observed were similar and are reported in Table 5. Nevertheless, ZTN deactivation surgery as described by Guyuron et al.<sup>23</sup> achieved the highest MH elimination / >50% reduction rates. However, results cannot be easily compared since most of the patients included in these studies underwent also other MH sites deactivations, either at the time of, before, or after site II/V surgeries.

### Authors' Experience

From June 2011 till January 2018, we have performed MH decompression surgery over 168 patients with either frontal, occipital, or temporal migraine trigger sites.<sup>7-11</sup>

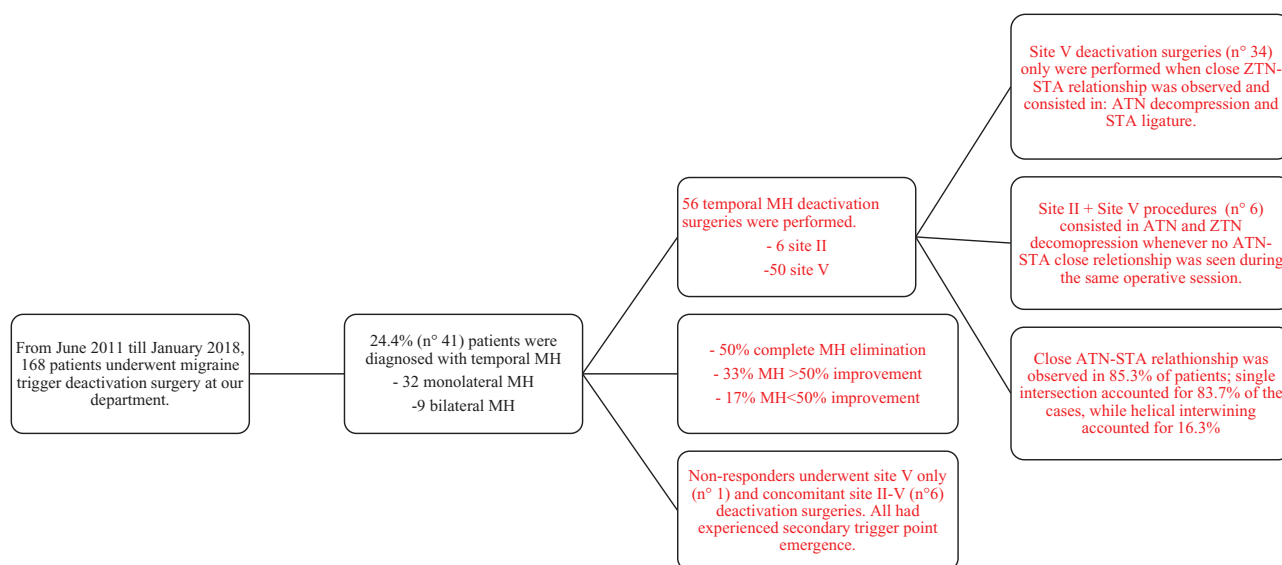


**Fig. 4.** Intraoperative picture: Ligation of the right STA.

Among them, 41 suffered from temporal migraine, 32 patients had monolateral MH, while 9 had bilateral one. We performed a total of 56 temporal migraine deactivation surgeries. Thirty-four surgeries were performed at site V only because ATN-STA close relationship was observed intraoperatively. Whereas site II and V deactivation procedures were performed during the same operative session 6 times, since no ATN-STA close relationship was encountered. Therefore, we observed ATN-STA close relationship in 85.3% of patients; single STA-ATN intersection accounted for 83.7% of the cases, while helical intertwining accounted for 16.3%.

**Table 5. Summary of Temporal Migraine Decompression Sites and Related Outcomes as Reported in Literature**

Author	No. Patients/Sites Treated	Addressed Nerve	Procedure	Complete Resolution	> 50% Improvement	< 50% or No Improvement
Guyuron et al. <sup>23</sup>	19 Patients (38 sites)	ZTN	Avulsion (19) Decompression (19)	57.9%	52.6%	5.3%
Gfrerer et al. <sup>24</sup>	32 sites	ZTN (27) ATN (5)	Avulsion Arterectomy/neurovascular bundle ligation	34.4%	40%	37%
Kurlander et al. <sup>28</sup>	246 Patients	ZTN	Avulsion	55%	30%	15%
Larson et al. <sup>27</sup>	/	ZTN	Avulsion/decompression	14.6%	61.2%	24.8%
Peled <sup>25</sup>	19 Patients	ZTN	Avulsion/decompression	37%	47%	16%
Sannic et al. <sup>26</sup>	30 Patients	ATN	Decompression + STA ligation	/	/	/
Raposo <sup>11</sup>	41 Patients (56 sites)	ATN (50) ZTN + ATN (6)	Decompression + STA ligation Decompression	50%	33.3%	16.7%



**Fig. 5.** Author’s personal experience with temporal MH deactivation surgery.

After a mean follow-up of 21 months (range, 3–67 months), patients complaining for temporal MH had 83% positive surgical outcome (50% complete MH elimination, 33% significant improvement). Seventeen percentage of patients did not notice any improvement since secondary trigger points occurred. Among these patients who had negative surgical outcome, 6 had concomitant site II and V deactivation surgeries while one had site V only deactivated (Fig. 5).

**Adverse Events**

Only rare minor complications are usually reported (eg, edema, hematoma/ecchymosis, numbness, and paresthesia). Numbness can occur (lasting <1 year, 163 days on average) in 5.7% of the patients.<sup>5</sup>

Intense itching, hypertrophic scar, incisional cellulitis, transient mild incisional alopecia, and hair thinning are also minor complications that have an incidence ranging from 1% to 5%. The most common complication after site II/V surgery is slight hollowing of the temple (54% incidence rate).<sup>2</sup>

Nerve avulsion may be associated with neuroma formation, although it is not reported in literature of any neuro- ma following avulsion of ATN and/or ZTN.<sup>22,29</sup> (Table 6)

Almost 90% of the patients can recognize more than 1 MH trigger site and surgical deactivation may be

**Table 6. Complications and Relative Incidences following Temporal Migraine Deactivation Surgery**

Complication	Incidence (%)
Slight temple hollowing	54
Secondary trigger point emergence	17.8
Lasting numbness (< 1 year)	5.7
Intense itching	5.7
Incisional alopecia/hair thinning	5
Hypertrophic scar	2.7
Incisional cellulitis	1

performed at all sites during the same surgical procedure depending on surgeon and patient preferences.<sup>12</sup> Furthermore, 17.8% of patients can experience secondary trigger point emergence following primary migraine surgery.<sup>30</sup>

MH recurrence may occur from 1 up to 3 months after surgery; thus, the result may be regarded as permanent only after the third postoperative month.<sup>5</sup>

**DISCUSSION**

Despite strenuous efforts in determining MH etiology, it is still a matter of debate whether it is of central

or peripheral genesis. Nevertheless, the striking results reported by surgeons performing decompression surgeries of trigger points in MH sufferers strongly support peripheral etiology of MH. Indeed various authors independently reported success rate higher than 80% in resolving or at least improving MH by decompressing irritated nerve from surrounding structures.<sup>31</sup> Nonresponders might either have been misdiagnosed in their MH, or have undergone incomplete surgical decompression, or even have trigger point not addressed at all. Just like upper extremity compressive neuropathies, MH may be the resulting epiphenomenon of chronic compression to cranial peripheral nerves.

Special relevance should be given to the close nerve/artery relationship that may intersect or intertwine each other, perhaps promoting irritation and therefore triggering MH attacks. Several studies have demonstrated a 34–80% rate of ATN-STA relationship, which may explain why some predisposed people have MH seemingly originating from this region.<sup>14,15</sup> The same pulsatile irritation was addressed as main etiology in site IV MH, where close interaction between great occipital nerve and occipital artery has a 54% rate.<sup>31,32</sup>

Wolff et al.<sup>33–37</sup> have provided clear evidences of the vasomotor mechanism producing head pain. While symptoms as scotomas, paresthesias, blurred speech, photo/phono-phobia are due to vasoconstriction of terminal branches of internal carotid artery, pulsatile distention of terminal branches of external carotid artery can determine traction and pressure stimuli to surrounding peripheral nerves deriving from the trigeminal nerve. This chronic irritation eventually results in throbbing, pulsating headache. In the later stage, antalgic contraction of surrounding muscles of head and neck can overcome the original vascular pain, resulting in chronic, dull, headache. For historical sake, Tunis and Wolff<sup>36</sup> managed temporal migraine by ligating STA in 1953. Our experience corroborate the “vascular” theory. When dealing with the occipital trigger sites, we usually found a close connection with dilated (or frankly aneurysmatic) occipital arteries, the ligation of whose completely deactivated this trigger point.<sup>38</sup> The same occurs when dealing with the AT site.

## CONCLUSIONS

Further studies need to be carried out to precisely delineate MH pathophysiology and to identify all potential compression points at trigger zones. Finally, in our humble opinion, particular attention should be paid in future to the nerve/artery relationship as one of MH causes.

**Edoardo Raposio, MD, PhD, FICS**

Department of Surgical Sciences

Plastic Surgery Division

University of Parma, Italy;

Cutaneous, Minimally Invasive, Regenerative  
and Plastic Surgery Unit

Parma University Hospital, Parma, Italy;

Via Gramsci 14, 43126, Parma, Italy.

E-mail: edoardo.raposio@unipr.it

## ACKNOWLEDGMENTS

*This study did not need any ethical approval since it did not describe experimental studies on either humans or animals. However, the study has been conducted in accordance with the principles outlined in the Declaration of Helsinki. All participants provided informed consent.*

## REFERENCES

- Guyuron B, Varghai A, Michelow BJ, et al. Corrugator supercilii muscle resection and migraine headaches. *Plast Reconstr Surg.* 2000;106:429–434; discussion 435.
- Janis JE, Barker JC, Javadi C, et al. A review of current evidence in the surgical treatment of migraine headaches. *Plast Reconstr Surg.* 2014;134:131–141.
- Guyuron B, Kriegler JS, Davis J, et al. Comprehensive surgical treatment of migraine headaches. *Plast Reconstr Surg.* 2005;115:1–9.
- Guyuron B, Reed D, Kriegler JS, et al. A placebo-controlled surgical trial of the treatment of migraine headaches. *Plast Reconstr Surg.* 2009;124:461–468.
- Guyuron B, Kriegler JS, Davis J, et al. Five-year outcome of surgical treatment of migraine headaches. *Plast Reconstr Surg.* 2011;127:603–608.
- Chmielewski L, Liu MT, Guyuron B. The role of occipital artery resection in the surgical treatment of occipital migraine headaches. *Plast Reconstr Surg.* 2013;131:351e–356e.
- Raposio E, Caruana G. Minimally invasive endoscopic surgical treatment of headache. In: *Atlas of Endoscopic Plastic Surgery* (Raposio E., ed.). New York, N.Y.: Springer; 2016: 17–21.
- Caruana G, Bertozzi N, Boschi E, et al. Endoscopic forehead surgery for migraine therapy personal technique. *Ann Ital Chir.* 2014;85:583–586.
- Raposio E, Caruana G. Frontal endoscopic myotomies for chronic headache. *J Craniofac Surg.* 2015;26:e201–e203.
- Caruana G, Grignaffini E, Raposio E. Endoscopic forehead muscle resection for nerve decompression: a modified procedure. *Plast Reconstr Surg Glob Open.* 2015;3:e342.
- Raposio E, Bertozzi N, Bordin C, et al. Surgical therapy of migraine and tension-type headaches. In: *Current Perspectives on Less-known Aspects of Headache*, (Turker H, Ed.), InTech, Zagreb, Croatia 2017; 93–114. DOI: 10.5772/64652.
- Guyuron B, Nahabet E, Khansa I, et al. The current means for detection of migraine headache trigger sites. *Plast Reconstr Surg.* 2015;136:860–867.
- Totonchi A, Pashmini N, Guyuron B. The zygomaticotemporal branch of the trigeminal nerve: an anatomical study. *Plast Reconstr Surg.* 2005;115:273–277.
- Chim H, Okada HC, Brown MS, et al. The auriculotemporal nerve in etiology of migraine headaches: compression points and anatomical variations. *Plast Reconstr Surg.* 2012;130:336–341.
- Janis JE, Hatef DA, Ducic I, et al. Anatomy of the auriculotemporal nerve: variations in its relationship to the superficial temporal artery and implications for the treatment of migraine headaches. *Plast Reconstr Surg.* 2010;125:1422–1428.
- Janis JE, Hatef DA, Thakar H, et al. The zygomaticotemporal branch of the trigeminal nerve: Part II. Anatomical variations. *Plast Reconstr Surg.* 2010;126:435–442.
- Iwanaga J, Watanabe K, Saga T, et al. Anatomical study of the superficial temporal branches of the auriculotemporal nerve: application to surgery and other invasive treatments to the temporal region. *J Plast Reconstr Aesthet Surg.* 2017;70:370–374.
- Iwanaga J, Bobek SL, Fisahn C, et al. An unusual finding of the auriculotemporal nerve: possible risk factor during preauricular skin incisions. *Gland Surg.* 2016;5:647–649.

19. Gülekon N, Anil A, Poyraz A, et al. Variations in the anatomy of the auriculotemporal nerve. *Clin Anat*. 2005;18:15–22.
20. Baumel JJ, Vanderheiden JP, McElenney JE. The auriculotemporal nerve of man. *Am J Anat*. 1971;130:431–440.
21. Andersen NB, Bovim G, Sjaastad O. The frontotemporal peripheral nerves. Topographic variations of the supraorbital, supratrochlear and auriculotemporal nerves and their possible clinical significance. *Surg Radiol Anat*. 2001;23:97–104.
22. Speciali JG, Gonçalves DA. Auriculotemporal neuralgia. *Curr Pain Headache Rep*. 2005;9:277–280.
23. Guyuron B, Harvey D, Reed D. A prospective randomized outcomes comparison of two temple migraine trigger site deactivation techniques. *Plast Reconstr Surg*. 2015;136:159–165.
24. Gfrerer L, Maman DY, Tessler O, et al. Nonendoscopic deactivation of nerve triggers in migraine headache patients: surgical technique and outcomes. *Plast Reconstr Surg*. 2014;134:771–778.
25. Peled ZM. A novel surgical approach to chronic temporal headaches. *Plast Reconstr Surg*. 2016;137:1597–1600.
26. Sanniec K, Borsting E, Amirlak B. Decompression—avulsion of the auriculotemporal nerve for treatment of migraines and chronic headaches. *Plast Reconstr Surg Glob Open*. 2016;4:e678. DOI: 10.1097/GOX.0000000000000663.
27. Larson K, Lee M, Davis J, et al. Factors contributing to migraine headache surgery failure and success. *Plast Reconstr Surg*. 2011;128:1069–1075.
28. Kurlander DE, Punjabi A, Liu MT, et al. In-depth review of symptoms, triggers, and treatment of temporal migraine headaches (Site II). *Plast Reconstr Surg*. 2014;133:897–903.
29. Corrales CE, Monfared A, Jackler RK. Facial and vestibulocochlear nerve avulsion at the fundus of the internal auditory canal in a child without a temporal bone fracture. *Otol Neurotol*. 2010;31:1508–1510.
30. Punjabi A, Brown M, Guyuron B. Emergence of secondary trigger sites after primary migraine surgery. *Plast Reconstr Surg*. 2016;137:712e–716e.
31. Polotto S, Simonacci F, Grignaffini E, et al. Surgical treatment of frontal and occipital migraines: a comparison of results. *Plast Reconstr Surg Glob Open*. 2016;4:e653.
32. Janis JE, Hatef DA, Reece EM, et al. Neurovascular compression of the greater occipital nerve: implications for migraine headaches. *Plast Reconstr Surg*. 2010;126:1996–2001.
33. Wolff HG, Tunis MM. Analysis of cranial artery pressure pulse waves in patients with vascular headache of the migraine type. *Trans Assoc Am Physicians*. 1952;65:240–244.
34. Tunis MM, Wolff HG. Analysis of cranial artery pulse waves in patients with vascular headache of the migraine type. *Am J Med Sci*. 1952;224:565–568.
35. Wolff HG, Tunis MM, Goodell H. Studies on headache: evidence of tissue damage and changes in pain sensitivity in subjects with vascular headaches of the migraine type. *Trans Assoc Am Physicians*. 1953;66:332–341.
36. Tunis MM, Wolff HG. Studies on headache; long-term observations of the reactivity of the cranial arteries in subjects with vascular headache of the migraine type. *AMA Arch Neurol Psychiatry*. 1953;70:551–557.
37. Tunis MM, Wolff HG. Studies on headache; long-term observation of alterations in function of cranial arteries in subjects with vascular headache of the migraine type. *Trans Am Neurol Assoc*. 1953;3(78th Meeting):121–123.
38. Raposio E, Caruana G. Tips for the surgical treatment of occipital nerve-triggered headaches. *Eur J Plast Surg*. 2017.40:177–182.